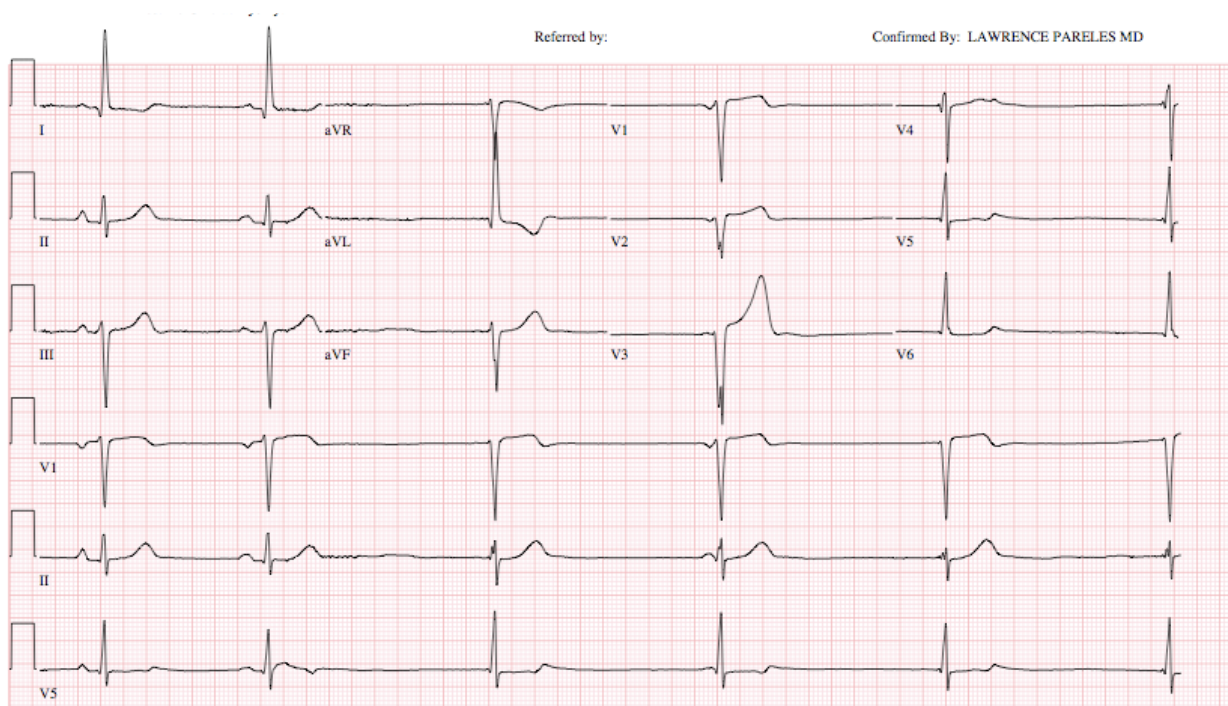


This 85 year old retired physician came in with complaints of tiredness. He had a past medical history of hypertension, dyslipidemia, gout, coronary artery disease, status post MI in the past, PCI and recent hospitalization with past atrial fibrillation. He'd had the gradual onset of weakness the same day, with dizziness but no syncope or dyspnea or chest pain.

His admission pulse was 32 and he was immediately brought to red pod where he had a bp of 142/95 and oxygen saturation of 98% on room air. He was in no acute distress at rest on gurney. Physical examination showed a few bibasilar râles.

EKG showed the following:



What is the rhythm?