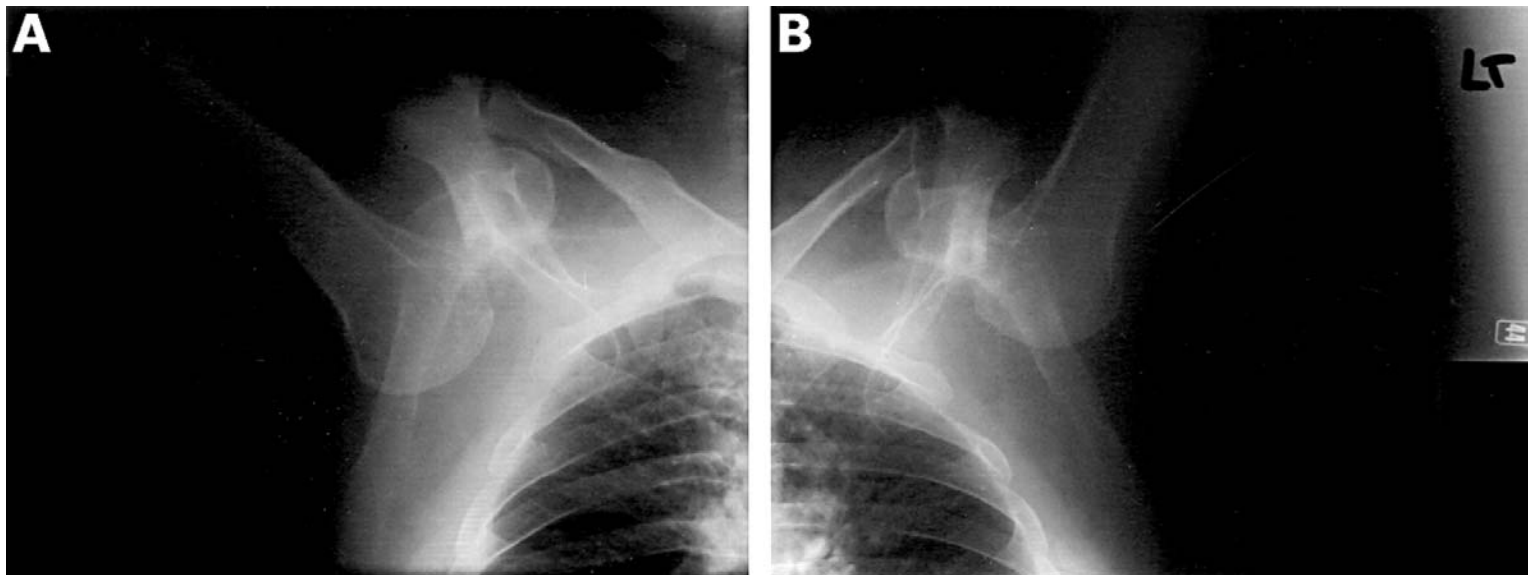


**Figure 1 Radiographs showing right (A) and left (B) inferior dislocation of shoulder.**



**Kumar, K S et al. Emerg Med J 2001;18:404-405**